

## Size and Aggregation of Corticosteroids Used for Epidural Injections

Richard Derby, MD,\*† Sang-Heon Lee, MD, PhD,\*§ Elaine S. Date, MD,† Joo-Han Lee, MD,‡ and Chang-Hyung Lee, MD, PhD\*†¶

\*Spinal Diagnostics and Treatment Center, Daly City, California, USA; †Division of Physical Medicine and Rehabilitation, Stanford University Medical Center, Stanford, California, USA; ‡Department of Pathology, §Department of Physical Medicine and Rehabilitation, Korea University Medical Center, Seoul, South Korea; and ¶Korea National Training Center, Kongneung-dong, Nowon-Gu, Seoul, South Korea

### ABSTRACT

*Objective.* The purpose of this study was to document particulate size in commonly used corticosteroid preparations. Inadvertent injection of particulate corticosteroids into a vertebral or foraminal artery can cause brain and spinal cord embolic infarcts and the size of the particles could be directly related to the chance that a clinically significant infarct would occur. One might assume that corticosteroids with particles significantly smaller than red blood cells might be safer.

*Design.* The following four types of corticosteroid preparations were used in various solutions and evaluated under light microscopy: dexamethasone sodium phosphate injection, triamcinolone acetate injectable suspension, betamethasone sodium phosphate and betamethasone acetate injectable suspension, and methylprednisolone acetate injectable suspension.

*Results.* Dexamethasone sodium phosphate particle size was approximately 10 times smaller than red blood cells and the particles did not appear to aggregate; even mixed with 1% lidocaine HCl solution and with contrast dye, the size of the particles were unchanged. Triamcinolone acetate and betamethasone sodium phosphate showed variable sizes; some particles were larger than red blood cells, and aggregation of particles was evident. Methylprednisolone acetate showed uniformity in size and the majority were smaller than red blood cells which were not aggregated, but the particles were densely packed.

*Conclusions.* Compared with the particulate steroid solutions, dexamethasone sodium phosphate had particles that were significantly smaller than red blood cells, had the least tendency to aggregation, and had the lowest density. These characteristics should significantly reduce the risk of embolic infarcts or prevent them from occurring after intra-arterial injection. Until shown otherwise in clinical studies, interventionalists might consider using dexamethasone or another corticosteroid preparation with similar high solubility and negligible particle size when performing epidural injections.

*Key Words.* Corticosteroid; Size of Particle; Epidural Injection; Embolic Infarction

### Introduction

Epidural injection of corticosteroids is a commonly used treatment for radicular pain [1–

11]. Although there are no controlled randomized trials evaluating the effectiveness of epidural steroid injections for treating upper extremity pain, prospective studies have shown significant reduction in extremity pain following transforaminal and interlaminar injection [1,12,13], and randomized controlled studies have shown the effective use of epidural injection of corticosteroids in relieving lower extremity pain [3,14–17].

*Reprint requests to:* Chang-Hyung Lee, MD, Korea National Training Center, 223-19, Kongneung-dong, Nowon-Gu, Seoul 139-242, South Korea. Tel: 82-2-970-0061; Fax: 82-2-970-0060; E-mail: chlee@sports.or.kr.

The interlaminar and transforaminal approaches are the most common methods used to access the cervical epidural space. The interlaminar approach typically achieves a multiple segmental dispersion of injected solutions. When radicular pain is caused by foraminal stenosis or disk protrusions, the transforaminal approach has the advantage of being more selective and is thus more likely to achieve a higher concentration of injected solution within the foramen [18–20].

Serious injury to the central nervous system has been reported following cervical transforaminal injection of corticosteroids [18,21–24]. These complications have prompted an ongoing debate on the risk vs the benefit of this procedure [23,25]. Although clinicians have performed hundreds, if not thousands, of cervical epidural steroid injections without injury to the spinal cord or brain, the exponential increase in the use of these procedures by a growing number of interventionalists contributes to the increasing number of reported and unreported complications. The most likely causes of these complications include the following [26,27]:

- spinal cord trauma following direct injection into the spinal cord;
- an infarction of the brain following injection of particulate corticosteroids into the vertebral artery;
- an infarction of the spinal cord following injection of particulate corticosteroids into a radicular or communicating artery;
- a compression of the spinal cord from an epidural hematoma or abscess; and
- an infarction of either the brain or the spinal cord secondary to spasm, physical trauma, or a compression of either the vertebral, the radicular, or a communicating artery.

Injuries involving the spinal cord are variations of anterior spinal artery syndrome [28]. “Anterior spinal artery syndrome is defined as complete motor paralysis with loss of pain and temperature sense, but sparing of position, vibration, and motion sense in the posterior columns. It occurs when the territory of the anterior spinal artery, supplying the ventral two-thirds of the spinal cord, is involved” [29]. Although injection into the vertebral artery should be recognized during the test injection of contrast medium, even with accurate needle placement and the injection of contrast, injection into a radicular or a communicating artery is difficult to detect due to the small diam-

eter and fleetingly brief flow of contrast medium [18,23].

One might assume that if a nonparticulate solution was injected into an artery, there would be little or no risk of an embolic infarct. In fact, some physicians advocate the use of a test dose of local anesthetic before the injection of particulate corticosteroids [23]. Injection of local anesthetic into a vertebral artery can cause a seizure, but if the airway and blood pressure are managed the patient should recover uneventfully within minutes. Although we can only speculate what would happen if a small dose were injected into a radicular artery, Karasek and Bogduk recently reported transient quadriplegia following the test dose of local anesthetic during a transforaminal epidural injection. The procedure was aborted and the patient recovered quickly and uneventfully [30].

Anecdotally, no serious complications have been cited that were caused by the injection of a nonparticulate steroid. However, the injection of particulate steroids has been associated with brain and spinal cord infarctions [12,22,23,31,32]. This is believed to occur because the size of particles in commonly used steroid preparations equals or exceeds the caliber of many arteries. Tiso et al. postulated that these complications were caused by embolism [32] and others have agreed that infarctions caused by particulate steroid emboli are a primary cause of complications [18,23,33]. In addition, one could logically propose that the greater the size of the particle, the greater the risk of obstruction in terminal arterioles.

Cerebellar infarction caused by the injection of particulate steroids into the vertebral artery is an event seen by experts reviewing litigated cases [26,34]. Similar to brain infarctions caused by the injection of particulate solutions into the vertebral artery [23,25,30,35], the injection of a particulate solution into a radicular or a communicating branch of the ascending or deep cervical artery is a likely cause of spinal cord infarcts [27]. Spasm or physical trauma to the artery is another potential, but less likely cause of these spinal cord infarcts. In addition, embolism can be caused by injected air [33,36–38].

Although researchers have examined various steroid mixtures under the microscope, to our knowledge no one has formally reported their observations. Moreover, there has been no study to determine whether nonparticulate steroids are safe. In all cases of misadventure reported in the

literature, particulate steroids have been used. No complications have been reported following the use of nonparticulate preparations.

In the following observational study, we evaluated the particle size of various commonly used corticosteroid mixtures. We compared the relative particle sizes in these preparations with the size of red blood cells and also observed particulate density and aggregation.

### Methods

Four proprietary steroid preparations were studied: Decadron<sup>®</sup> (Baxter Healthcare Corp., Deerfield, IL), Kenalog<sup>®</sup> (Bristol-Myers Squibb Company, Princeton, NJ), Celestone Soluspan<sup>®</sup> (Schering, Kenilworth, NJ) and Depo-Medrol<sup>®</sup> (Pharmacia & Upjohn, Kalamazoo, MI). Various standard concentrations of these agents were examined, along with certain mixtures.

Each milliliter of Decadron<sup>®</sup> 4 mg/mL contains dexamethasone sodium phosphate equivalent to 4 mg dexamethasone phosphate or 3.33 mg dexamethasone. Inactive ingredients per milliliter are: 8 mg creatinine, 10 mg sodium citrate, sodium hydroxide to adjust pH, and water for injection q.s., with 1 mg sodium bisulfite, 1.5 mg methylparaben, and 0.2 mg propylparaben added as preservatives. Dexamethasone sodium phosphate forms a white or slightly yellow crystalline powder. It is freely soluble in water and is exceedingly hygroscopic. Infusion solutions generally do not contain preservatives [39].

Kenalog<sup>®</sup>-10 and Kenalog<sup>®</sup>-40 are sterile aqueous suspensions that contain 10 mg/mL or 40 mg/mL triamcinolone acetonide, respectively; sodium chloride for isotonicity; 0.9% (w/v) benzyl alcohol; 0.75% carboxymethylcellulose sodium; and 0.04% polysorbate 80. In some solutions, sodium hydroxide or hydrochloric acid may be added by the manufacturer to adjust pH to between 5.0 and 7.5 [39].

Each milliliter of Celestone Soluspan<sup>®</sup> contains 3.0 mg betamethasone as betamethasone sodium phosphate; 3.0 mg betamethasone acetate; 7.1 mg dibasic sodium phosphate; 3.4 mg monobasic sodium phosphate; 0.1 mg edentate disodium; and 0.2 mg benzalkonium chloride. Betamethasone sodium phosphate is a sterile, aqueous suspension with a pH of between 6.8 and 7.2. It is a white to off-white, or creamy white, odorless powder and is hygroscopic. It is practically insoluble in water, but freely soluble in acetate, and is soluble in alcohol and chloroform [39].

Preparations of Depo-Medrol<sup>®</sup> 40 mg/mL contain methylprednisolone 40 mg; polyethylene glycol 29.1 mg; polysorbate 80 1.94 mg; monobasic sodium 6.8 mg; dibasic sodium phosphate United States Pharmacopeia (USP) 1.42 mg; and benzyl alcohol preservative 9.16 mg. Methylprednisolone acetate is a white or off-white, odorless, crystalline powder that is soluble in dioxane; sparingly soluble in acetone, alcohol, chloroform, and methanol; and slightly soluble in ether. It is practically soluble in water [39].

The preparations studied were Decadron<sup>®</sup> 4 mg/mL; Decadron<sup>®</sup> 10 mg/mL; Kenalog<sup>®</sup> 10 mg/mL; Kenalog<sup>®</sup> 40 mg/mL; Celestone<sup>®</sup> 6 mg/mL; and Depo-Medrol<sup>®</sup> 40 mg/mL. Certain mixtures were also prepared and examined to assess if a local anesthetic (lidocaine; Abbott Laboratories, Abbot Park, IL) or contrast medium (iohexol; Omipaque<sup>™</sup>; Amersham Health, Cork, Ireland) affected solubility or aggregation of steroid particles. The mixtures were Decadron<sup>®</sup> 4 mg/mL mixed 1:1 with 1% lidocaine HCl injection; Decadron<sup>®</sup> 10 mg/mL mixed 1:1 with 1% lidocaine HCl injection; Decadron<sup>®</sup> 10 mg/mL mixed 1:1:1 with 1% lidocaine HCl injection and iohexol injection 240 mg/mL; Depo-Medrol<sup>®</sup> 40 mg/mL mixed 1:1 with 1% lidocaine HCl injection; and Depo-Medrol<sup>®</sup> 40 mg/mL mixed 1:1:1 with 1% lidocaine HCl injection and iohexol injection 240 mg/mL.

Each of the steroid solutions and mixtures was distributed on a glass slide over an area approximately 1 cm in diameter. All slides were coded. With a light microscope, each slide was examined at two magnifications ( $\times 400$  and  $\times 1,000$ ), in five areas, and photographed. Evaluations were made independently by three investigators, one of whom is a pathologist. To document the size of red blood cells, more than 40 separate slides were prepared, each utilizing a drop of blood. Red blood cells were stained with toluidine blue and measured.

### Results

The various steroid preparations and mixtures exhibited different physical features in terms of particle size, density, and the prevalence and size of aggregates (Table 1). At a magnification of  $\times 400$ , red blood cells were observed to be 7.5–7.8  $\mu\text{m}$  in diameter, and provided a reference for the size of steroid particles and aggregates.

#### Dexamethasone

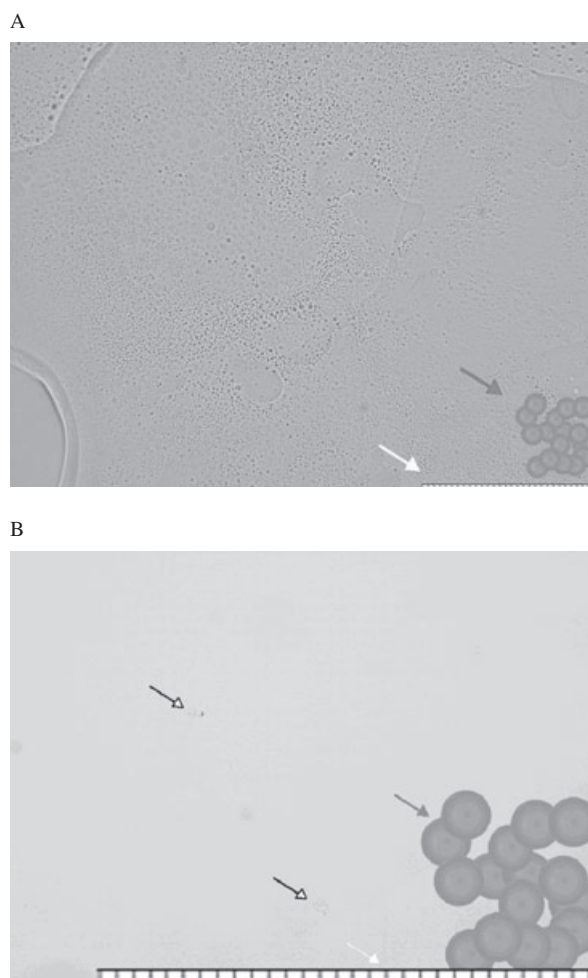
In both 4 mg/mL and 10 mg/mL solutions, the majority of dexamethasone particles measured

**Table 1** Size of Steroid particles, comparison with red blood cells


Size of Steroid Particles In Comparison with Size of Red Blood Cells (7.5–7.8 $\mu\text{m}$ )		DMSP 4 mg/ml	DMSP 10 mg/ml	DMSP with Lidocaine	DMSP + Lidocaine + dye	TAA 10 mg/ml	TAA 40 mg/ml	BSP and BMA 6 mg/ml	Methyl Prednisone 40 mg/ml	Methyl Prednisone 40 mg/ml + lidocaine + dye
Particle size	<7.6	<7.6	<7.6	<7.6	<7.6	0.5–>100	0.5–>100	Varied	<7.6	<7.6
Concentration	Few particles	Few particles	Few particles	Few particles	Few particles	Densely packed	Densely packed	Densely packed	Densely packed	Densely packed
Aggregation	None	None	None	None	None	Extensive	Extensive	Aggregates >100	Few	Few
Comparison	<RBC	<RBC	<RBC	<RBC	<RBC	12 times RBC size	12 times RBC size	12 times RBC size	Densely packed	Densely packed

0.5  $\mu\text{m}$ —much smaller in diameter than red blood cells (Table 1). The smallest dexamethasone particles were too small to be measured, even at  $\times 1,000$  microscopic magnification. Fewer than 20 particles in each view field were observed in both solutions, and there was no apparent aggregation in either solution (Figure 1).

The mixtures of dexamethasone and local anesthetic, and of dexamethasone, local anesthetic, and contrast medium showed features like those of dexamethasone alone (Figure 2). There were fewer than 20 particles per field, at  $\times 1,000$  magnification, and no aggregation was observed



**Figure 1** Microscopic finding of 4 mg/mL dexamethasone (A:  $\times 400$ , B:  $\times 1,000$ ); the majority of particles were 0.5  $\mu\text{m}$ . Red blood cells, 7.5–7.8  $\mu\text{m}$  are illustrated on the right bottom (black arrow). Each unit on the scale indicates 2.45  $\mu\text{m}$  (white arrow). Even at  $\times 1,000$  microscopic view, the size of the particles were so small to be measured. Only some relatively big particles were observed (white-tipped arrows), but still much smaller than the size of red blood cells.



**Figure 2** Under  $\times 1,000$  microscopic finding of 10 mg/mL dexamethasone mixed with lidocaine and mixed with lidocaine and radioactive dye; the majority of particles were  $0.5 \mu\text{m}$ . Red blood cells,  $7.5\text{--}7.8 \mu\text{m}$  are illustrated on the right bottom (black arrow). Each unit on the scale indicates  $2.45 \mu\text{m}$  (white arrow). Mixed with lidocaine and lidocaine with radioactive dye, the size remained the same and no aggregation was observed.

(Table 1). However, the mixtures did appear to be more viscous.

#### *Triamcinolone*

In the 10 mg/mL solution of triamcinolone, particles varied in size, ranging from  $0.5 \mu\text{m}$  to larger than  $100 \mu\text{m}$ . Similar particle size was observed in the 40 mg/mL solution of triamcinolone (Table 1). The largest of particles were more than 12 times greater than median-sized red blood cells. Particles were darkish and were observed to be densely packed. Extensive aggregation was observed (Figure 3).

#### *Betamethasone*

Particles of betamethasone were rod-shaped and varied in size. Some particles were extremely small at  $\times 1,000$ . The particles were densely packed, and extensive aggregation was observed, including some large aggregations exceeding  $100 \mu\text{m}$  (Figure 4). The larger aggregations of betamethasone were more than 12 times greater than the size of red blood cells.

#### *Methylprednisolone*

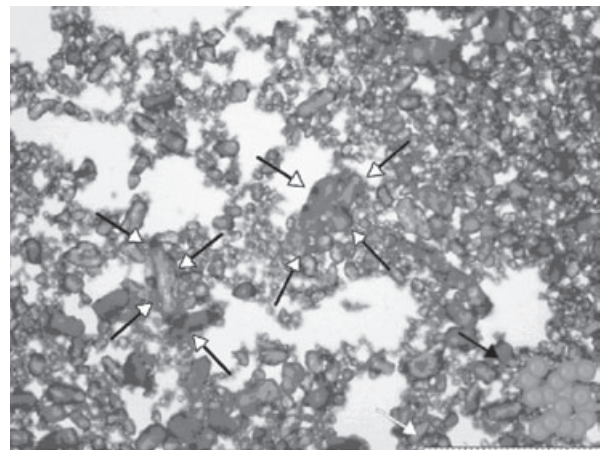
Methylprednisolone particles were relatively uniform in size, and most were smaller than red blood cells. Particles were densely packed, but few aggregations were observed (Table 1). Most particles and aggregations were smaller than red blood

cells (Figure 5). However, the propensity of the particles to pack densely suggests that they could form an embolus, possibly capable of occluding a small arteriole. The mixture of methylprednisolone and local anesthetic and methylprednisolone with local anesthetic and contrast medium exhibited the same features as methylprednisolone alone, and few aggregates were seen (Figure 6).

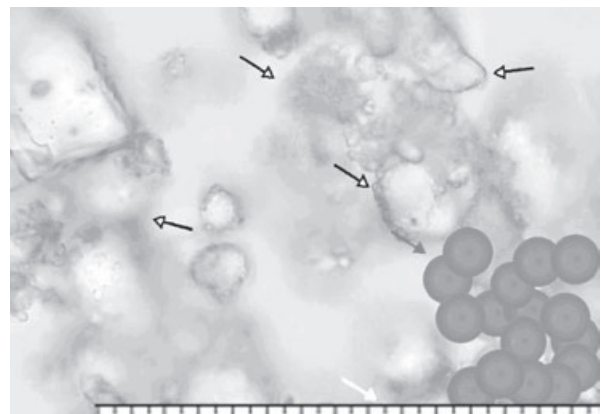
#### Discussion

Rosenkranz et al. [21] have shown that the pathophysiologic mechanism of spinal cord infarction may be due to hemodynamic compromise (e.g., vasospasm or mechanical pressure due to injected fluid volume) of a cervical artery. However, embolic occlusion of cord arterioles following acciden-

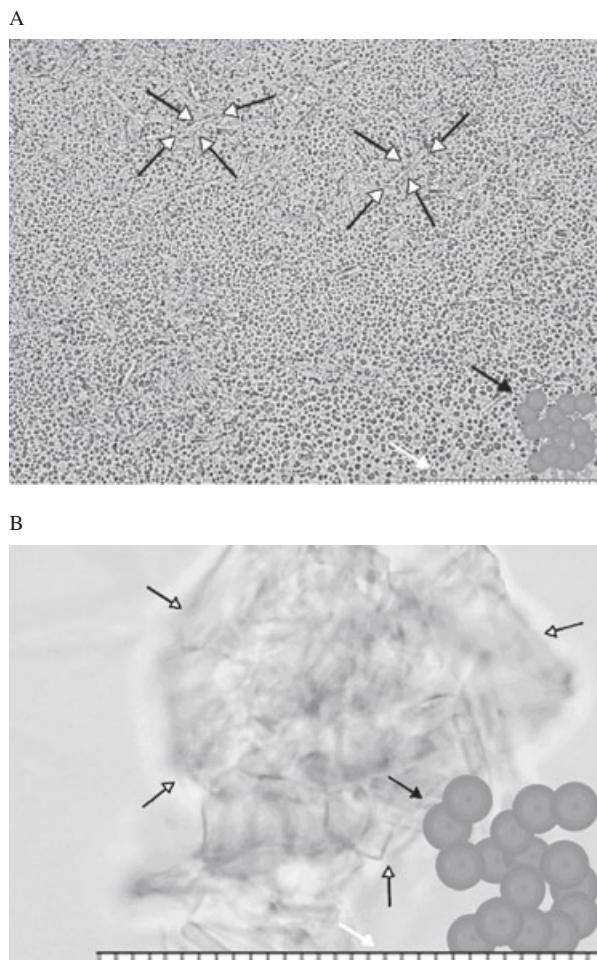
A



B



**Figure 3** Microscopic findings of 40 mg/mL triamcinolone acetonide (A:  $\times 400$ , B:  $\times 1,000$ ); large aggregations were observed (white-tipped arrows). Red blood cells are illustrated on the right bottom (black arrow). Each unit on the scale indicates  $2.45 \mu\text{m}$  (white arrow).



**Figure 4** Microscopic findings of 6 mg/mL betamethasone sodium phosphate and betamethasone acetate (Celestone Soluspan®) (A:  $\times 400$ , B:  $\times 1,000$ ). Rod-shaped aggregations were observed (white-tipped arrows). Red blood cells are illustrated on the right bottom (black arrow). Each unit on the scale indicates 2.45  $\mu\text{m}$  (white arrow).


tal intra-arterial injection of crystalline corticoid suspension may be more likely. Rosenkranz et al. reported that the size of some triamcinolone acetonide microcrystals exceeded 20  $\mu\text{m}$  in diameter (mean 4.5  $\mu\text{m}$ ), and intravascular precipitation of microcrystals could result in aggregation of much larger particles that could be sizeable enough to occlude small vessels of the microcirculation [21].

The most commonly used corticosteroid preparations all have different solubility and aggregation characteristics. Our results show that the four most commonly used steroids have a range of physical properties, with particles of differing size, water solubility, and tendency to aggregate.

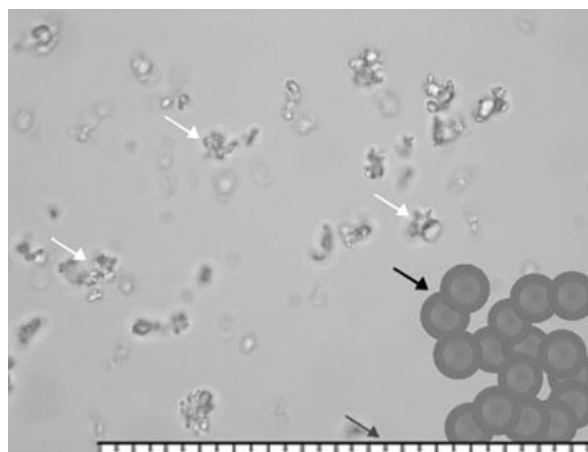
Dexamethasone particles measured 0.5  $\mu\text{m}$  and were five to 10 times smaller than red blood

cells. They were soluble in water and showed no aggregation.

In terms of metabolic activity, dexamethasone has a rapid onset but short duration of action when compared with less soluble preparations [40]. Given the short duration of action, some clinicians view other particulate corticosteroids as more



**Figure 5** Microscopic finding of 40 mg/mL methylprednisolone acetate injectable suspension (Depo-Medrol®) ( $\times 1,000$ ). Small and densely packed particles were observed (white arrows), but there was no noticeable aggregation. Red blood cells are illustrated on the right bottom (black arrow). Each unit on the scale indicates 2.45  $\mu\text{m}$  (gray arrow).



**Figure 6** Microscopic finding of 40 mg/mL methylprednisolone acetate injectable suspension (Depo-Medrol®) mixed 1:1:1 with 1% lidocaine HCl injection 10 mg/mL and radioactive contrast dye ( $\times 1,000$ ). Small and densely packed particles were observed (white arrows), but there was no noticeable aggregation. Red blood cells are illustrated on the right bottom (black arrow). Each unit on the scale indicates 2.45  $\mu\text{m}$  (gray arrow).

appropriate therapeutic choices. However, recent research by Dreyfuss et al. evaluating relative effectiveness of particulate and nonparticulate steroids found no clinically or statistically significant difference in immediate efficacy [41].

Particles of triamcinolone vary greatly in size, from 0.5  $\mu\text{m}$  to 100  $\mu\text{m}$ . The majority are substantially larger than red blood vessels. The particles pack densely, and have a tendency to aggregate and form precipitates. The particles of betamethasone vary in size. They are less than 5  $\mu\text{m}$ , but some tend to aggregate. The aggregates exceed 10  $\mu\text{m}$ , which is larger than red blood cells.

The particles of methylprednisolone are uniformly smaller than red blood cells and, although densely packed, they seem not to aggregate.

The present study was limited to observing various dissolved corticosteroid preparations *in vitro* under a microscope. It would be difficult to perform these studies *in vivo* in live blood, given its visual density. Therefore, it is not possible to determine if particle size and aggregation would increase or decrease in flowing blood could. However, if particles of a particular steroid are considerably smaller than the size of a red blood cell, are soluble in water, and do not aggregate, one might logically assume that such a steroid would be less likely to cause a symptomatic embolism if injected into an artery. Observed under a microscope, both dexamethasone and methylprednisolone acetate particles were smaller than red blood cells, were water soluble, and did not aggregate. However, methylprednisolone acetate was observed to be densely packed, which suggests increased potential for forming an embolus.

### Conclusion

Compared with triamcinolone acetonide injectable suspension, betamethasone acetate injectable suspension, and methylprednisolone acetate injectable suspension, dexamethasone sodium phosphate has the smallest particle size and is the least densely concentrated. Particles of dexamethasone sodium phosphate are, on average, 5–10 times smaller than red blood cells and do not aggregate. These findings suggest that dexamethasone is less likely to cause arterial or capillary obstruction if inadvertently injected into a vertebral or foraminal artery. As the efficacy of nonparticulate corticosteroids may be comparable to that of particulate corticosteroids, interventionalists might consider using a nonparticulate steroid

when performing cervical transforaminal injections.

### References

- 1 Rowlingson JC, Kirschenbaum LP. Epidural analgesic techniques in the management of cervical pain. *Anesth Analg* 1986;65:938–42.
- 2 Zhou Y, Furgang FA, Zhang Y. Quality assurance for interventional pain management procedures. *Pain Physician* 2006;9:107–14.
- 3 Spaccarelli KC. Lumbar and caudal epidural corticosteroid injections. *Mayo Clin Proc* 1996;71:169–78.
- 4 Hession WG, Stanczak JD, Davis KW, Choi JJ. Epidural steroid injections. *Semin Roentgenol* 2004;39:7–23.
- 5 Bogduk N, Aprill C, Derby R. Epidural steroid injections. In: White AH, ed. *Spine Care, Volume One: Diagnosis and Conservative Treatment*, ch. 22. St Louis: Mosby; 1995:322–43.
- 6 Thomas E, Cyteval C, Abiad L, Picot MC, Taourel P, Blotman F. Efficacy of transforaminal versus interspinous corticosteroid injection in discal radiculalgia—a prospective, randomised, double-blind study. *Clin Rheumatol* 2003;22:299–304.
- 7 Slipman CW, Chow DW. Therapeutic spinal corticosteroid injections for the management of radiculopathies. *Phys Med Rehabil Clin N Am* 2002;13:697–711.
- 8 Carette S, Leclaire R, Marcoux S, et al. Epidural corticosteroid injections for sciatica due to herniated nucleus pulposus. *N Engl J Med* 1997;336:1634–40.
- 9 Buchner M, Zeifang F, Brocai DR, Schiltenswolf M. Epidural corticosteroid injection in the conservative management of sciatica. *Clin Orthop* 2000;149–56.
- 10 Weinstein SM, Herring SA, Derby R. Contemporary concepts in spine care. Epidural steroid injections. *Spine* 1995;20:1842–6.
- 11 Cuckler JM, Bernini PA, Wiesel SW, Booth RE Jr, Rothman RH, Pickens GT. The use of epidural steroids in the treatment of lumbar radicular pain. A prospective, randomized, double-blind study. *J Bone Joint Surg Am* 1985;67A:63–6.
- 12 Cicala RS, Westbrook L, Angel JJ. Side effects and complications of cervical epidural steroid injections. *J Pain Symptom Manage* 1989;4:64–6.
- 13 Shulman M. Treatment of neck pain with cervical epidural steroid injection. *Reg Anesth* 1986;11:92.
- 14 Riew KD, Yin Y, Gilula L, et al. The effect of nerve-root injections on the need for operative treatment of lumbar radicular pain. A prospective, randomized, controlled, double-blind study. *J Bone Joint Surg Am* 2000;82A:1589–93.
- 15 Hodge J. Facet, nerve root, and epidural block. *Semin Ultrasound CT MR* 2005;26:98–102.
- 16 Aydin SM, Zou SP, Varlotta G, Gharibo C. Successful treatment of phantom radiculopathy with

- fluoroscopic epidural steroid injections. *Pain Med* 2005;6:266–8.
- 17 Bosacco SJ, Bosacco DN, Berman AT, Cordover A, Levenberg RJ, Stellabotte J. Functional results of percutaneous laser discectomy. *Am J Orthop* 1996;25:825–8.
  - 18 Rathmell JP, Aprill C, Bogduk N. Cervical transforaminal injection of steroids. *Anesthesiology* 2004;100:1595–600.
  - 19 Akkaya T, Sayin M. [Transforaminal epidural steroid injection and its complications]. *Agri* 2005;17:27–39.
  - 20 Harney DF, Shaikhani J, Van Zundert J, Van Kleef M. Transforaminal epidural corticosteroid injection: Rational evidence-based practice. *Reg Anesth Pain Med* 2005;30:206; author reply 208–210.
  - 21 Rosenkranz M, Grzyska U, Niesen W, et al. Anterior spinal artery syndrome following periradicular cervical nerve root therapy. *J Neurol* 2004;251:229–31.
  - 22 Brouwers PJ, Kottink EJ, Simon MA, Prevo RL. A cervical anterior spinal artery syndrome after diagnostic blockade of the right C6-nerve root. *Pain* 2001;91:397–9.
  - 23 Baker R, Dreyfuss P, Mercer S, Bogduk N. Cervical transforaminal injection of corticosteroids into a radicular artery: A possible mechanism for spinal cord injury. *Pain* 2003;103:211–5.
  - 24 Rozin L, Rozin R, Koehler SA, et al. Death during transforaminal epidural steroid nerve root block (C7) due to perforation of the left vertebral artery. *Am J Forensic Med Pathol* 2003;24:351–5.
  - 25 Derby R. Transforaminal vs interlaminar steroid injections. *Spine* 2004;6:16–21.
  - 26 Derby R, Lee S-H, Kim B-J, Chen Y, Seo KS. Complications following cervical epidural steroid injections by expert interventionalists in 2003. *Pain Physician* 2004;7:445–9.
  - 27 Huntoon MA. Anatomy of the cervical intervertebral foramina: Vulnerable arteries and ischemic neurologic injuries after transforaminal epidural injections. *Pain* 2005;117:104–11.
  - 28 Suh DC, Kim SJ, Jung SM, Park MS, Lee JH, Rhim SC. MRI in presumed cervical anterior spinal artery territory infarcts. *Neuroradiology* 1996;38:56–8.
  - 29 Cheshire WP, Santos CC, Massey EW, Howard JF Jr. Spinal cord infarction: Etiology and outcome. *Neurology* 1996;47:321–30.
  - 30 Karasek M, Bogduk N. Temporary neurologic deficit after cervical transforaminal injection of local anesthetic. *Pain Med* 2004;5:202–5.
  - 31 Huntoon MA, Martin DP. Paralysis after transforaminal epidural injection and previous spinal surgery. *Reg Anesth Pain Med* 2004;29:494–5.
  - 32 Tiso RL, Cutler T, Catania JA, Whalen K. Adverse central nervous system sequelae after selective transforaminal block: The role of corticosteroids. *Spine J* 2004;4:468–74.
  - 33 McMillan MR, Crumpton C. Cortical blindness and neurologic injury complicating cervical transforaminal injection for cervical radiculopathy. *Anesthesiology* 2003;99:509–11.
  - 34 Aprill CN, Dumitrescu M. Adverse central nervous system sequelae after selective transforaminal block: The role of corticosteroids. *Spine J* 2005;5:475.
  - 35 Derby B, Dreyfuss P. Cervical radicular pain: Transforaminal vs interlaminar steroid injections. *Spine* 2004;16–21.
  - 36 Muth CM, Shank ES. Gas embolism. *N Engl J Med* 2000;342:476–82.
  - 37 Hinkle DA, Raizen DM, McGarvey ML, Liu GT. Cerebral air embolism complicating cardiac ablation procedures. *Neurology* 2001;56:792–4.
  - 38 Akhtar N, Jafri W, Mozaffar T. Cerebral artery air embolism following an esophagogastrosopy: A case report. *Neurology* 2001;56:136–7.
  - 39 Barsamian DN. *Physicians' Desk Reference*, 58th edn. Montvale, NJ: Thomson PDR; 2004.
  - 40 Balderston RA, Albert TJ, McIntosh T, Wong L, Dolinskas C. Magnetic resonance imaging analysis of lumbar disc changes below scoliosis fusions. A prospective study. *Spine* 1998;23:54–8.
  - 41 Dreyfuss P, Baker R, Bogduk N. Comparative effectiveness of cervical transforaminal injections with particulate and nonparticulate corticosteroid preparations for cervical radicular pain. *Pain Med* 2006;7:237–42.