

Painful Lumbar End-Plate Disruptions: A Significant Discographic Finding

KEN Y. HSU, MD, JAMES F. ZUCHERMAN, MD, RICHARD DERBY, MD, ARTHUR H. WHITE, MD, NOEL GOLDTHWAITE, MD, and GAR WYNNE, MD

Of the 692 discs injected during lumbar discograms, end-plate disruptions with leakage of contrast material into the vertebral bodies were noted in 14 discs. Although gentle pressure was applied during the injections, severe fully concordant pain was reproduced in four (28.3%) discs, moderately severe and fully concordant pain in nine (64.3%) discs, and mild discordant pain in one (7.4%) disc. This is compared to 11.2% of the remaining 678 discs without end-plate disruption that reproduced severe concordant pain, 31.1% with moderately severe concordant pain, 17.1% with mild pain, and 40.6% without any pain reproduction. The difference between pain frequency in discs with end-plate disruption and those without is statistically significant ($P < .001$). This suggests that end-plate disruptions may be related to painful segments. [Key words: discography, end-plate disruption, pain reproduction]

DISCOGRAPHY PROVIDES unique and useful information in evaluation of suspected discogenic pain. Although controversial, it is the only test that attempts to measure pain emanating from the annulus fibrosus and that exhibits internal disc architecture. The authors have found the radiographic entity of end-plate disruption to be related to concordant pain reproduction at a statistically significant frequency.

PATIENTS AND METHODS

During the first 10 months of 1986, diagnostic lumbar discographies were performed on 218 patients with histories of low-back pain. Their ages ranged from 18 to 76 years old. There were a total of 692 discs that were injected with conray. The number of discs injected per patient ranged from one to five. A mean of three discs was injected in each patient. The two-needle posterolateral technique was used for each disc while the patient was under local anesthesia.

Of the 692 discs, end-plate disruptions were noted in 14 discs in 12 patients, with leakage of contrast material into the vertebral bodies visualized on radiographs obtained 5 to 15 minutes after the injection. All 12 patients had previous fourth generation computed tomography (CT) scans.

There were seven men and five women with such end-plate disruptions. Their ages at the time of the discographic study ranged from 18 to 52 years, with a mean of 32.9 years.

Of the 12 patients, four had a history of significant trauma. One man jumped out of a moving boxcar 30 months prior to the discogram. Another man was involved in a motor vehicle accident 16 months before the discogram. One woman landed on her sacrum after speeding down a long slide in an amusement park 29 months before the study. Another woman struck her coccyx against the

concrete floor while roller skating 6 years earlier. There were five patients who were involved in heavy-lifting injuries 9 to 32 months prior to the discographic studies. There was no definite history of trauma in three patients, although one aircraft mechanic claimed cumulative stress to his back from working in tight spaces. One woman was a ballet dancer. Two patients had previous surgeries, although the discs in question were not removed. End-plate disruptions were noted above a two-level fusion in one man, and within a three-level fusion in one woman.

The end-plate disruptions were noted at the vertebra above the injected discs in 12 patients. Two end-plate disruptions occurred at S1 with leakage of the contrast material into the sacrum.

RESULTS

Although gentle pressure was applied during the injections, severe fully concordant pain was reproduced in four (28.3%) discs. Moderately severe and fully concordant pain was reproduced in nine (64.3%) discs. Mild discordant pain was noted in only one (7.4%) disc within a three-level fusion in a woman.

This compares to 76 (11.2%) discs of the remaining 678 discs without end-plate disruption that reproduced severe concordant pain. Two hundred eleven (31.1%) discs had moderately severe concordant pain reproduction. One hundred sixteen (17.1%) discs had mild pain reproduction. Two hundred seventy-five (40.6%) discs of the 678 did not have any pain reproduction.

The difference between pain frequency in discs with end-plate disruption and those without is statistically significant ($P < .001$) by χ^2 . This suggests that end-plate disruptions may be related to painful segments.

DISCUSSION

It is not uncommon to see movement of radiopaque dye from the disc injection into the veins of the vertebral bodies during discography. Crock³ showed an example of L3-4 discogram with a normal nuclear outline but with spread of contrast into the vertebral veins. Tributaries of the anterior internal vertebral plexus and Batson's plexus were filled. These venous fillings occur rapidly and disappear within seconds. The discographic pattern documented in our 14 discs are distinctly different from such venous fillings. The leakage of conray into the vertebral bodies through the end-plates was filmed on roentgenographs 5 to 15 minutes after the injections.

Some of our discographic patterns were similar to those of McCall et al,⁶ who reviewed eight cases of end-plate rupture and acute traumatic intraosseous disc herniations. Their cases were found in adolescent patients with severe, prolonged back pain following compression/flexion injury to the spine. The condition was confirmed by discography and reproduction of symptoms during the injection. The authors documented the evolution of these lesions with sequential radiographs from a stage of poor definition to marginal sclerosis and cortication to differentiate them from the static appearance seen in typical Schmorl's nodes and Scheuermann's disease.

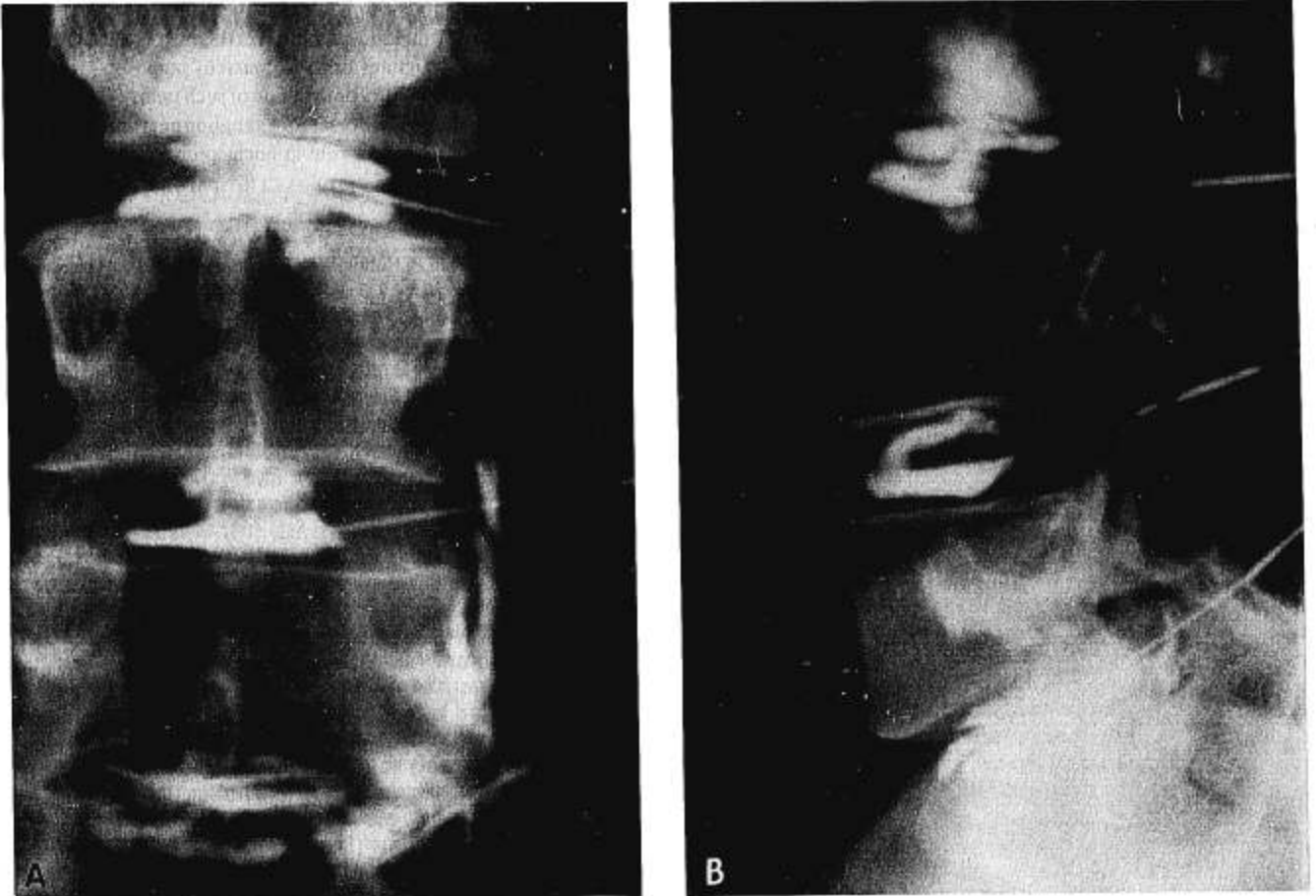


Fig 1. **A**, AP X-ray film showing end-plate disruption at L3-4 level with leakage of contrast material into the L3 vertebral body filmed more than 10 minutes after the injection. Although gentle pressure was applied during the injection, severe fully concordant back pain was reproduced in this patient. **B**, Lateral x-ray film of the same patient.

McCall et al⁶ attributed the cause to rupture of the end-plate followed by intraosseous disc herniation. The process was believed to be more frequent during the growth phase of an adolescent. The distribution is predominantly at the thoracolumbar region, in contrast to our cases that were noticed mostly in the lower three lumbar levels in the third and fourth decades. The condition described by McCall et al and our end-plate disruptions may represent variations of the same disease process.

At least three of our patients had severe axial loading of the vertebral column, while five other patients were involved in lifting heavy loads. It is known that only the intervertebral disc is deformed at small loads. The vertical stress is converted to horizontal mode by the nucleus pulposus. The stress then is absorbed by the annulus fibrosus. The end-plate and the vertebral body are deformed with increasing force at a greater rate than the disc. Virgin,¹⁰ Brown et al,² Roaf,⁷ Smith,⁹ Jayson et al,⁵ and Rolander and Blair,⁸ found that axial loading of the spine to the point of failure causes end-plate disruption rather than damage to the annulus fibrosus. Rolander and Blair⁸ demonstrated the formation of a central stellate fissure in the end-plate with load not exceeding that for fracture. In cases where fracture loads were exceeded, there were gross transverse or sagittal fractures. The disc content then burst into the vertebral body. Jayson et al⁵ found globular nucleus pulposus in younger spines. In his study, most globular discs burst directly into the vertebral body with axial loading when compared to other nuclear morphologies. As expected,

the discs in osteoporotic spines burst with lower pressure into the vertebral bodies. Roaf⁷ has found that when significant disc degeneration is present, compression injury produces general collapse of the vertebral body rather than a localized fracture.

Adam et al¹ performed discograms in 139 discs from cadaveric lumbar spines that were then sectioned for further examination. The appearance of the discogram was found to be related to the state of disc degeneration. There were five discs with the dye leaking into the vertebral bodies, thus revealing end-plate fractures. They were all found in the upper three lumbar levels, in contrast to our cases that involved the lower three levels predominantly. Two of Adam's cases were of Type 2 discs, which are mature discs with nuclei starting to coalesce into fibrous lumps. There were Type 5 discs with complete radial fissures that allowed the injected fluid to escape. Our cases are similar to those of Adam et al¹ in that end-plate disruptions are not necessarily related to disc degeneration.

There is no clear explanation of the cause of pain in end-plate disruptions. End-plate disruption may involve significant injury or irritation to the nerve supply that is closely associated with the adventitial sheaths of the blood vessels that ramify through the cancellous bone and into the subchondral region of the end-plate. These are plexuses of unmyelinated nerve fibers that constitute an intramedullary nociceptive receptor system.¹²

Jackson et al⁴ found the nerve supply of the end-plates to be in close association with the vascular sinusoids in the developing tissues

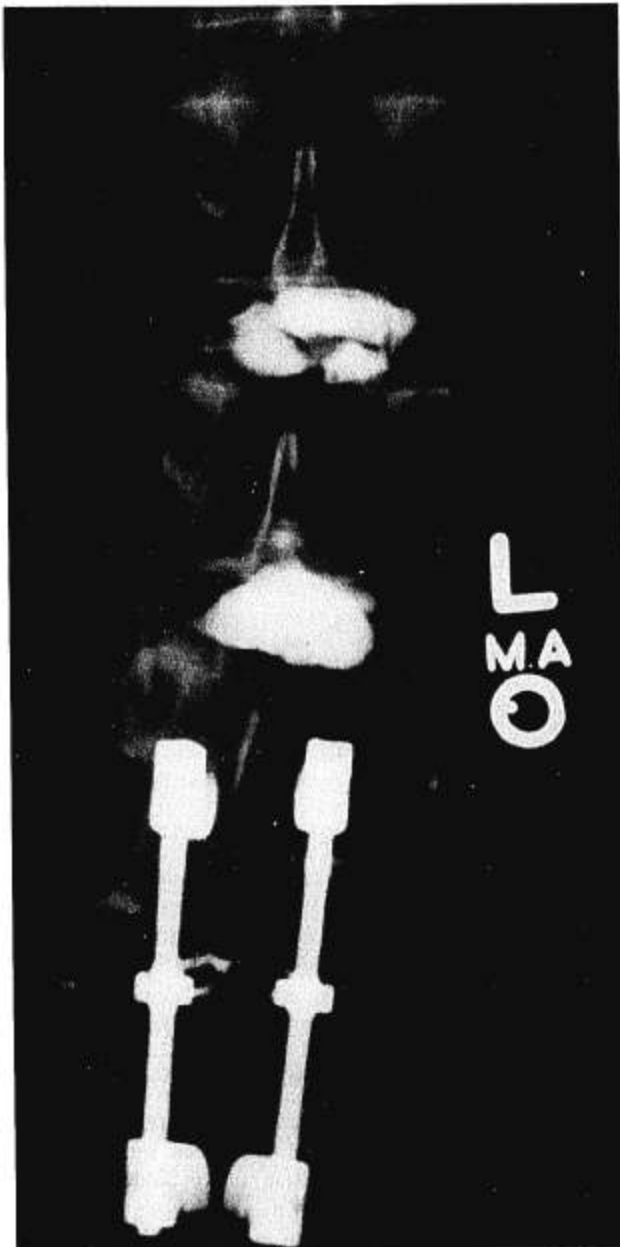

Fig 2. End-plate disruption at the level above a Knodt rod fusion. The contrast material leaked into the vertebral body above the injected disc.

of the fetuses and infants. In adult specimens, fine free nerve fibers were observed in all anatomic locations in the vertebra, except in the deeper zones of the annulus or in the nucleus pulposus.

It is possible that the injury or irritation of such unmyelinated nerve fibers may in turn affect the dorsal root ganglion neuropeptides, such as substance P, which play a role in nociceptor transmission.¹¹

REFERENCES

1. Adams MA, Dolan P, Hutton WC: The Stages of disc degeneration as revealed by discograms. *J Bone Joint Surg* 68B:36, 1986
2. Brown T, Hansen RJ, Yorra AJ: Some mechanical tests on the lumbosacral spine with particular reference to the intervertebral discs. *J Bone Joint Surg* 39A:1135, 1957.
3. Crock HV: *Practice of Spinal Surgery*. Vienna, Springer-Verlag, 1983
4. Jackson HC, Winkelmann RK, Bickel WH: Nerve endings in the human lumbar spinal column and related structures. 48A:1272-1281, 1966.
5. Jayson MIV, Herbert CM, Barks, JS: Intervertebral discs: nuclear morphology and bursting pressures. *Ann Rheum Dis* 32:310, 1973
6. McCall IW, Park WM, O'Brien JP, Seal V: Acute traumatic intraosseous disc herniations. *Spine* (10):134, 1985
7. Roaf R: A study of the mechanics of spinal injuries. *J Bone Joint Surg* 428:810, 1960
8. Rolander SF, Blair WE: Deformation and fracture of the lumbar vertebral endplate. *Orthop Clin North Am* (6):75, 1975
9. Smith FP: Experimental biomechanics of intervertebral disc rupture through vertebral body. *J Neurosurg* 30:134, 1969
10. Virgin WJ: Experimental investigations into the physical properties of the intervertebral disc. *J Bone Joint Surg* 33B:607, 1951
11. Weinstein J: Mechanisms of spinal pain—The dorsal root ganglion and its role as a mediator of low-back pain. *Spine* (11): 999, 1986
12. Wyke B: Receptor systems in lumbosacral tissue in relation to the production of low back pain. *American Academy of Orthopaedic Surgeons, Symposium on Idiopathic Low Back Pain*. St. Louis, CV Mosby, 1982

Address reprint requests to

Ken Y. Hsu, MD
San Francisco Orthopaedic Surgeons
 4141 Geary Boulevard
 San Francisco, CA 94118

Accepted for publication July 24, 1987.