

## COMPLICATIONS FOLLOWING CERVICAL EPIDURAL STEROID INJECTIONS BY EXPERT INTERVENTIONALISTS IN 2003

Richard Derby, MD, Sang-Heon Lee, MD, PhD, Byung-Jo Kim, MD, PhD, Yung Chen, MD, and Kwan Sik Seo, MD

**Background:** Two major portals are available for delivery of medication into the cervical epidural space: interlaminar and transforaminal. The choice of which approach to use is commonly made by assessing the patient's structural pathology, one's skill in performing each procedure, and then weighing the advantages versus the risk associated with the particular technique. Over the past several years, a growing number of cases involving serious complications following cervical transforaminal epidural steroid injections have led some to question the safety of the procedure and to preferentially perform interlaminar epidural injections

**Objective:** To explore the prevalence of complications caused by transforaminal versus interlaminar.

**Design:** Retrospective survey.

**Methods:** We selected the list of course instructors of the International Spine

Intervention Society (ISIS) as our source for expert spine injection specialists. All data were collected by survey during a period from April 2004 through June 2004.

Questions were asked about the type of cervical epidural injections performed and any complications during the preceding 12 months, January through December 2003.

**Results:** All 29 ISIS course instructors were surveyed. Seventeen instructors replied. In 2003, an estimated total of 5968 cervical epidural injections were performed by 17 instructors for neck and/or arm pain. The interlaminar approach was performed in 4389 cases by 14 instructors and the transforaminal approach was used in 1579 cases by 16 of the instructors.

Of the 4389 interlaminar injections there were 23 cases (0.52%) of various minor complications including headaches caused by dural puncture, transient vagal

episodes, and prolonged complaints of new or increased numbness and paresthesias.

In the 1579 transforaminal there were five cases (0.32%) of minor complications including aggravated radicular pain, prolonged paresthesias, and skin rashes. In addition, 2 cases of radicular artery injection were confirmed by digital subtraction angiography during 354 transforaminal approaches performed by one physician.

The rates of complication were not different between interlaminar and transforaminal approaches.

**Conclusion:** When performed by experienced interventionalists, major complications are probably rare and it could take years for a significant complication to occur. We must however all be aware that these complications can occur.

**Keywords:** Cervical epidural, interlaminar, transforaminal, fluoroscopy

The injection of corticosteroids into the epidural space is commonly used to treat radicular pain (1, 2) Although there are randomized controlled studies supporting short-term effectiveness of epidural steroid injections (ESIs) in relieving lower extremity pain, there are no published randomized control studies evaluating the effectiveness of cervical epidural steroid injections. (3, 4) However, there are prospective studies documenting a significant reduction in extremity pain following transforaminal and inter-

laminar cervical ESIs (1, 5, 6). Despite the ongoing debate on the long term outcome following epidural corticosteroid injections (2, 7, 8), prolonged pain relief may depend on the underlying structural and psychological pathology. When the structural pathology does not require surgical decompression or stabilization to relieve neural compression and significant pain persists despite several weeks of rest and oral medication, acutely reducing epidural inflammation and edema by the precise application of corticosteroids may be a reasonable next option.

Two major portals are available for delivery of medication into the cervical epidural space: interlaminar and transforaminal. The choice of which approach to use is commonly made by assessing the patient's structural pathology, one's skill in performing each procedure, and then weighing the advantages versus the risks associated the particular tech-

nique. When multilevel pathology is present the interlaminar route may facilitate multilevel spread. More localized spread can be achieved by using a transforaminal approach and many believe that this technique is the most specific and effective method for delivering medications (8-10), especially when pain is caused by foraminal or extraforaminal disc herniations (11-13).

When considering epidural injections, whether interlaminar or transforaminal, the ongoing concern is the risk of serous injury to the central nervous system, from such factors as needle placement, intravascular injection and the use of particulate steroid preparations.. Central nervous system injury may occur as a result of direct injection of particulate corticosteroids into the spinal cord, infarction of the brain following injection of particulate corticosteroids into the vertebral artery, infarction of the spinal cord

From Spinal Diagnostics and Treatment Center, Daly city, CA, Stanford University Medical Center, Stanford, CA and Korea University Medical Center, Seoul, Korea

Address Correspondence: Kwan Sik Seo, MD, PhD, 901 Campus Dr, #312, Daly City, CA 94015

Disclaimer: There was no external funding in preparation of this manuscript.

Conflict of Interest: None

Manuscript received on: September 20, 04

Accepted for publication on: September 28, 04

following injection of particulate corticosteroids into a radicular artery, or compression of the spinal cord from an epidural hematoma or abscess (14-16). Although most experts have performed hundreds if not thousands of cervical epidural steroid injections without causing injury to the nervous system, the large increase in the use of these procedures by "newly trained" interventionalists may be contributing to an increasing number of reported and unreported complications.

Over the past several years, the perceived growing number of cases involving serious complications following cervical transforaminal epidural steroid injections has led some to question the safety of the procedure and to preferentially perform interlaminar epidural injections. In fact, the safe risk/benefit ratio for performing any type of cervical epidural injection has been questioned. The present survey was undertaken in an effort to explore the emerging controversy about complications occurring during or after cervical transforaminal and interlaminar ESIs. We chose a panel of expert interventionalists to help reduce the possibility that the perceived increased in occurrence of complications is caused by faulty technique. In addition, we evaluated the prevalence (the number of reported complications as a function of the total number of injections reported) and types of complications caused by transforaminal and interlaminar ESIs. Because we were relying on physician recall, estimates of the numbers and types of injections performed, and the numbers and types of complications, our inquiry was limited to a period of 12 months.

## METHODS

We selected the list of course instructors of the International Spine Intervention Society (ISIS) as our source for expert spine injection specialists. All data were collected with survey during a period from April 2004 through June 2004. All surveys were anonymous, and course instructors did not know the purpose of this survey. Questions were asked about the type of cervical epidural injections (total number of cases, the number of interlaminar or transforaminal approaches), why a particular insertion level was chosen with the interlaminar approach, and complications (the number of complications, precise descriptions of

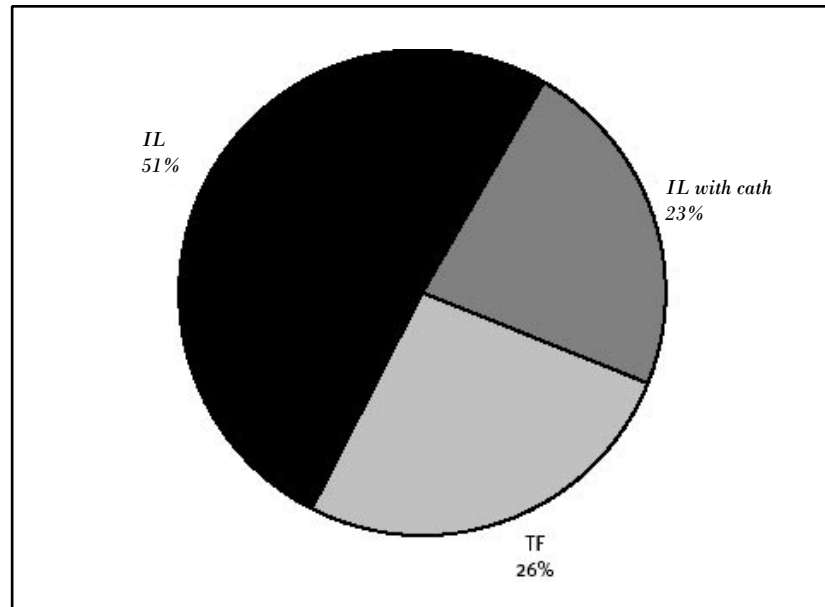


Fig 1. *Distribution of procedure type for epidural injections in 2003. With cervical epidural injections, the interlaminar (IL) epidural approach was preferred (73%). TF: transforaminal approach).*

complications, the types of ESI approach used, when complications occurred, etc.) during the preceding 12 months, from January through December 2003. We used the chi-square test to compare the rates of complications between interlaminar and transforaminal approaches.

## RESULTS

We sent the form to all 29 ISIS course instructors of which 17 instructors replied. In 2003, an estimated total of 5968 cervical epidural injections were performed by 17 instructors for neck and/or arm pain. The interlaminar approach was performed in 4389 cases by 14 instructors and the transforaminal approach was used in 1579 cases by 16 of the instructors (Fig. 1). Of the 4389 interlaminar approaches, 1360 cases were performed by 3 instructors using a catheter.

## Complications

Overall, 28 complications (0.47%) were reported. In the 4389 interlaminar injections there were 23 instances (0.52%) of various minor complications including headaches caused by dural puncture, transient vagal episodes, and prolonged complaints of new or increased numbness and paresthesias (Figure 2). In the 1579 transforaminal cases there

were five instances (0.32%) of minor complications including aggravated radicular pain, prolonged paresthesias, and skin rashes (Figure 3). In addition, 2 cases of radicular artery injection were confirmed by digital subtraction angiography during 354 transforaminal approaches performed by one physician; presumably corticosteroid injections were not done in those instances. The rates of complications were not different between interlaminar and transforaminal approaches ( $X^2=0.040$ ,  $p>0.05$ , Figure 4)

## Insertion Level

Sixteen physicians preferentially used the interlaminar approach. Six choose the T1-T2 or C7-T1 because the distance from the ligamentum flavum to the dural sac is greatest at this level. Four instructors chose the symptomatic or pathologic level of the cervical spine. Two instructors chose the C7/T1 interlaminar space as the needle insertion site regardless of symptomatic level. One instructor preferred a level at or cephalad to C5/6 because the shoulder shadow obscured the lateral fluoroscopic image at lower cervical levels. Three interventionalists used a catheter passed from an epidural needle placed at the C7-T1 level.

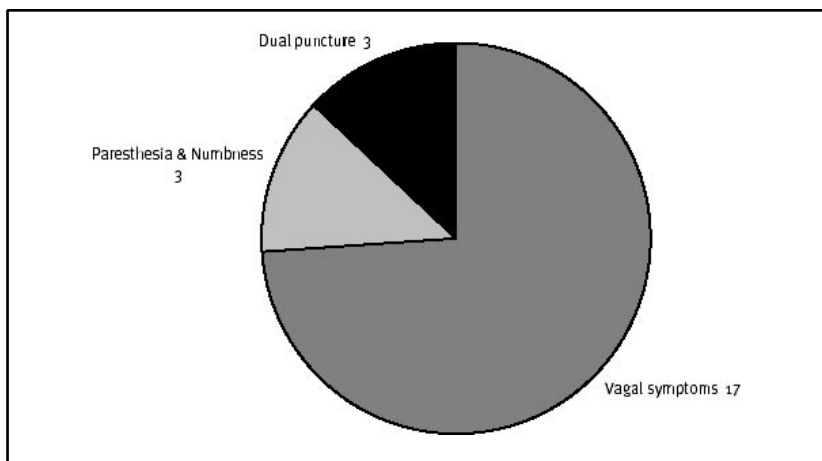


Fig 2. Complications during interlaminar epidural injections in 2003

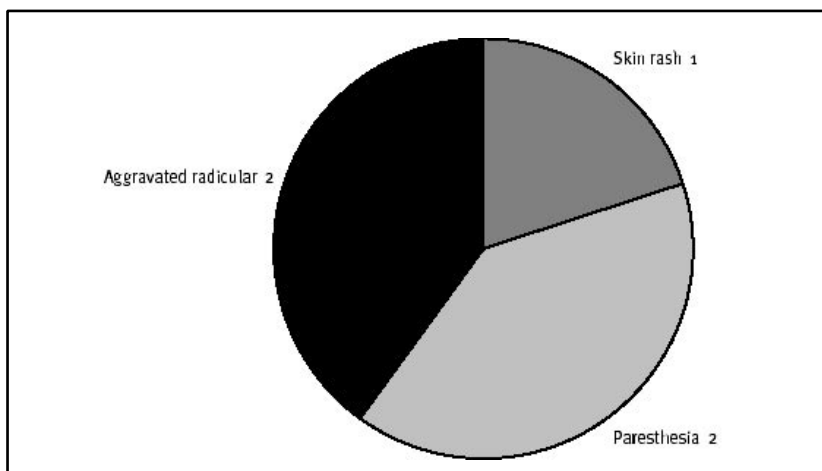


Fig 3. Complications during transforaminal epidural injections in 2003

cases are reporting an increasing number of serious complications following transforaminal epidural injections, and some interventionalists have abandoned the transforaminal approach.(20) Consistent with this apparent trend in the year 2003 the 17 surveyed members performed 73.5% of the 5968 cervical epidural injection using an interlaminar approach.

Published reports of complications following interlaminar epidural blocks are small in number. A report describing two cases of cord injury secondary to probable needle penetration and injection into the cervical cord occurred after interlaminar epidural blocks performed at the same level as a disc protrusion. A case commentary by Derby (21) and a subsequent article by Kaplan et al (22) make suggestions to help prevent these type of injuries and an upcoming editorial by Derby et al (23) will continue the risk/benefit debate of performing either transforaminal or interlaminar cervical epidural injections.

Because of the self-reporting nature of this survey and the fact that the response rate was only 59%, the prevalence of serious complications following cervical transforaminal and interlaminar injections remains speculative. Physicians who had major complications within the last year might be reluctant to participate in the survey. If one assumes that there were not more than one or two major complications unreported by the 12 interventionalists who did not return the

**DISCUSSION**

The prevalence of complications or events that could potentially cause complications remains under-reported. A recent review by Dr. Robert Windsor discusses causes and methods to help prevent complications caused by transforaminal cervical epidural injections (17). Furman et al (18) reported a high prevalence of intravascular penetration with cervical transforaminal epidural injections (19.4%; 98 vascular injections of 504 injections). Recently, the first case of death during cervical transforaminal epidural steroid nerve root block (C7) was reported (19). The autopsy findings found massive cerebral edema secondary to dissection of the left vertebral artery and subsequent thrombosis due to perforation of that artery by a 25-gauge spinal needle (19). Although published reports are few, experts reviewing medical malpractice

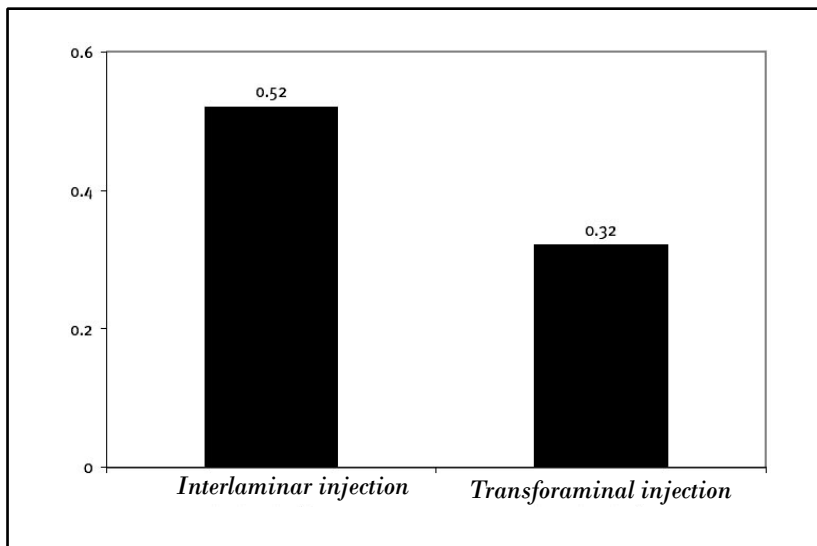


Fig 4. Complication rate during cervical interlaminar and transforaminal epidural injections in 2003. There was no statistically significant difference in complication rates between the two approaches ( $P > 0.05$ ).

survey, the prevalence is probably somewhere between one major complication in 2 to 5 thousand cases. Three respondents did comment on a total of 7 cases of central nervous system infarcts and one death that occurred during or after cervical epidural injections performed by other "less experienced" members of their community. Most of those cases involved injection of particulate corticosteroids. Because injections into a radicular artery can be difficult to detect, others and we have switched to using a short acting non-particulate corticosteroid and local anesthetic (e.g. dexamethasone phosphate ~ 2mg + 0.5 ml 1% lidocaine) when performing cervical transforaminal epidural injections.

The 0.52 % and 0.32 % prevalence of estimated minor complications with cervical interlaminar and transforaminal injections, respectively, may underestimate the true prevalence of complications, because of poor recall, incomplete follow-up, unwillingness to report complications, or a combination thereof. Post procedural pain flare-ups are probably closer to 10% rather than the 4.2% reported by the respondents. One could argue that a transient increase in pain is not a complication and only two of the 17 respondents reported pain exacerbation as a complication. Similarly, vagal episodes during procedures occasionally occur, treatment is usually straightforward, and such events are usually not considered procedural complications. Occasional dural punctures occur after interlaminar or transforaminal epidurals, but only one respondent stated that injection of local anesthetic required assisted ventilation (by mask for about 15 to 30 minutes). Nerve root injury due to trauma from a sharp needle is possible, but only two respondents noted 5 cases of transient numbness and paresthesias, and only one reported two cases of more prolonged increase in nerve root symptoms.

When performing an interlaminar cervical epidural injection, most responding interventionalists placed the needle at a level that provided the most distance between the ligamentum flavum and the dura and most choose either the C7-T1 or T1-T2 levels. Aldrete et al (24) reported that T1-T2 has the widest distance from ligamentum flavum to dural sac (0.5 cm) and ligamentum flavum to

spinal cord (1.0 cm) in a retrospective review study of cervical spine MRI images of 100 patients. In addition, there are gaps in the ligamentum flavum in the midline which are common at the upper cervical levels (25), and difficulties in identifying the epidural space using the loss of resistance technique have been reported (26). Typically those using a midline approach at the upper cervical levels rely on the lateral fluoroscopic image to confirm proper needle position.

The reason 41% of those queried did not return the survey may be due to disinterest, but a few may have been restrained because of medical legal concerns. The prevalence of major complications following cervical epidural injections will be difficult to determine using a volunteer-based survey. Retrospective estimations or prospective follow-up methods could be done on single or multi-center practices, but when performed by experienced interventionalists, major complications are probably rare and it could take years for major complications to occur. However, we must be aware that these complications can occur. A weekend cadaver course does not qualify one to perform these procedures and even those with experience might reconsider the risk/benefit ratio of performing cervical transforaminal, and perhaps interlaminar, epidural injections.

#### CONCLUSION

Reported complications were rare following cervical ESIs, whether by the interlaminar or transforaminal technique, when performed by physicians experienced in interventional pain management. Differences in reported complication rates between the two approaches were not statistically significant. Overall, there were about 5 minor complications per 1000 epidural injections. The prevalence of major complications was not ascertained by this study. To answer this question, much larger studies must be performed. However, the potential serious consequences of such complications require that these procedures be performed with the utmost vigilance.

#### Author Affiliation:

##### Richard Derby, MD

Spinal Diagnostics and Treatment Center  
901 Campus Dr.  
Daly City, CA 94015  
Division of Physical Medicine and Rehabilitation  
Stanford University Medical Center  
300 Pasteur Dr.  
Stanford, CA 94305  
E-mail: richard@spinaldiagnostics.com

##### Sang-Heon Lee, MD, PhD

Spinal Diagnostics and Treatment Center  
901 Campus Dr.  
Daly City, CA 94015

##### Byung-Jo Kim, MD, PhD

Spinal Diagnostics and Treatment Center  
901 Campus Dr.  
Daly City, CA 94015  
Department of Neurology  
Korea University Medical Center  
Seoul, Korea

##### Yung Chen, MD

Spinal Diagnostics and Treatment Center  
901 Campus Dr.  
Daly City, CA 94015

##### Kwan Sik Seo, MD, PhD

Research Physician  
Spinal Diagnostics and Treatment Center  
901 Campus Dr, #312  
Daly City, CA 94015  
E-mail:seo@spinaldiagnostics.com

#### REFERENCES

1. Rowlingson JC, Kirschenbaum LP. Epidural analgesic techniques in the management of cervical pain. *Anesth Analg* 1986; 65: 938-942.
2. Bush K, Hillier S. Outcome of cervical radiculopathy treated with periradicular/epidural corticosteroid injections: A prospective study with independent clinical review. *Eur Spine J* 1996; 5:319-325.
3. Karppinen J, Ohinmaa A, Malmivaara A et al. Cost effectiveness of periradicular infiltration for sciatica: subgroup analysis of a randomized controlled trial. *Spine* 2001; 26:2587-2595.
4. Riew KD, Yin Y, Gilula L et al. The effect of nerve-root injections on the need for operative treatment of lumbar radicular pain. A prospective, randomized, controlled, double-blind study. *J Bone Joint Surg Am* 2000; 82-A:1589-1593.

5. Cicala RS, Westbrook L, Angel JJ. Side effects and complications of cervical epidural steroid injections. *J Pain Symptom Manage* 1989; 4:64-66.
6. Shulman M. Treatment of neck pain with cervical epidural steroid injection. *Reg Anesth* 1986; 11:92.
7. Weinstein SM, Herring SA. Lumbar epidural steroid injections. *Spine J* 2003; 3:37S-44S.
8. Bogduk N, Christophidis N, Cheny D. Epidural steroids in the management of back pain and sciatica of spinal origin. Report of the working party on epidural use of steroids in management of back pain. In *National Health and Medical Research Council: Canberra, Australia, 1993*.
9. Bogduk N, Aprill C, Derby R. Epidural steroid injections. In White AH (ed). *Spine Care Operative Treatment*. Mosby, St. Louis, 1995 pp 322-342.
10. Woodard J, Herring S, Windsor R et al. Epidural procedures in spine pain and management. In *Physiatric Procedures in Clinical Practice*. Lennard T (ed). Hanka and Belfus, Philadelphia, 1995, pp 260-291.
11. Derby R, Kine G, Saal JA et al. Response to steroid and duration of radicular pain as predictors of surgical outcome. *Spine* 1992; 17:S176-183.
12. Weiner BK, Fraser RD. Foraminal injection for lateral lumbar disc herniation. *J Bone Joint Surg Br* 1997;79: 804-807.
13. Kraemer J, Ludwig J, Bickert U et al. Lumbar epidural perineural injection: A new technique. *Eur Spine J* 1997; 6:357-361.
14. Brouwers PJ, Kottink EJ, Simon MA et al. A cervical anterior spinal artery syndrome after diagnostic blockade of the right C6-nerve root. *Pain* 2001; 91:397-399.
15. Bromage PR, Benumof JL. Paraplegia following intracord injection during attempted epidural anesthesia under general anesthesia. *Reg Anesth Pain Med* 1998; 23: 104-107.
16. Adriani J, Naragi M. Paraplegia associated with epidural anesthesia. *South Med J* 1986; 79:1350-1355.
17. Windsor RE, Storm S, Sugar R et al. Cervical transforaminal injection: Review of the literature, complications, and a suggested technique. *Pain Physician* 2003; 6:457-465.
18. Furman MB, Giovanniello MT, O'Brien EM. Incidence of intravascular penetration in transforaminal cervical epidural steroid injections. *Spine* 2003; 28:21-25.
19. Rozin L, Rozin R, Koehler SA et al. Death during transforaminal epidural steroid nerve root block (C7) due to perforation of the left vertebral artery. *Am J Forensic Med Pathol* 2003; 24:351-355.
20. Aprill C. Injections: How, where, by whom, if ever - Transforaminal corticosteroids. In *ISIS 12th Annual Scientific Meeting: Wailea Maui Hawaii, 2004*.
21. Derby R. Cervical Radicular Pain: Transforaminal vs. interlaminar steroid injections. *SpineLine* 2004; 5:16-21.
22. Kaplan M, Derby R. Epidural corticosteroid injections: When, why, and how. *J Musculo Med* 1998; 15:39-46.
23. Derby R, Kim BJ, Lee SH et al. Cervical Interlaminar Epidural Injection. In *International Spinal Injection Society 12th Annual Scientific Meeting: Maui, Hawaii, 2004*.
24. Aldrete JA, Mushin AU, Zapata JC. Skin to cervical epidural space distances as read from magnetic resonance imaging films: Consideration of the "hump pad." 1998; 10:309-313.
25. Lirk P, Kolbitsch C, Putz G et al. Cervical and high thoracic ligamentum flavum frequently fails to fuse in the midline. *Anesthesiology* 2003; 99:1387-1390.
26. Stojanovic MP, Vu TN, Caneris O et al. The role of fluoroscopy in cervical epidural steroid injections: an analysis of contrast dispersal patterns. *Spine* 2002; 27:509-514.

